

## 고칼슘혈증 동반 사르코이드증에서 정상 혈중 비타민 D를 보인 증례

경북대학교 의학전문대학원 <sup>1</sup>내과학교실, <sup>2</sup>병리과학교실

전재한<sup>1</sup> · 서정범<sup>1</sup> · 황인량<sup>1</sup> · 박혜윤<sup>1</sup> · 김정식<sup>2</sup> · 박근규<sup>1</sup> · 김정국<sup>1</sup>

### Case of Sarcoidosis-Related Hypercalcemia with Normal Serum 1,25(OH)<sub>2</sub>D

Jae-Han Jeon<sup>1</sup>, Jung-Bum Seo<sup>1</sup>, In-Ryang Hwang<sup>1</sup>, Hye-Yoon Park<sup>1</sup>,  
Jeong-Shik Kim<sup>2</sup>, Keun-Gyu Park<sup>1</sup>, and Jung-Guk Kim<sup>1</sup>

*Departments of <sup>1</sup>Internal Medicine and <sup>2</sup>Pathology, Kyungpook National University School of Medicine, Daegu, Korea*

Diagnosing hypercalcemia is often challenging because a wide spectrum of diseases-such as malignancy, granulomatous disease, and primary hyperparathyroidism-should be considered. Sarcoidosis is a rare cause of hypercalcemia. The case of a 77-year-old male presenting with sarcoidosis-associated hypercalcemia whose serum 1,25(OH)<sub>2</sub>D level was normal is reported here. Despite a normal 1,25(OH)<sub>2</sub>D level and minimally enlarged hilar lymphadenopathy, the serum angiotensin-converting enzyme (ACE) level was increased. Mediastinoscopic biopsy of the right lower paratracheal lymph node revealed pathological findings compatible with sarcoidosis. Treatment with 30 mg/day oral prednisone was started. Currently, the patient is being treated with a tapered dose of oral prednisone and small doses of vitamin D and calcium. Despite its low incidence, sarcoidosis should be considered a cause of hypercalcemia. The important diagnostic factors are not only serum calcitriol levels but also serum ACE levels and pathological findings. (Korean J Med 2015;88:207-211)

**Keywords:** Hypercalcemia; Sarcoidosis; Vitamin D

#### INTRODUCTION

Sarcoidosis is an inflammatory disease of unknown cause that affects multiple organs and is characterized by the accumulation

of non-caseating granulomas [1]. The organs most commonly affected are the lungs, skin, eyes, and extrathoracic lymph nodes, and the course is usually benign and self-limiting. However, while approximately two-thirds of patients with sarcoidosis

Received: 2013. 11. 22

Revised: 2014. 1. 7

Accepted: 2014. 7. 11

Correspondence to Jung-Guk Kim, M.D., Ph.D.

Division of Endocrinology and Metabolism, Department of Internal Medicine, Kyungpook National University School of Medicine, 130 Dongdeok-ro, Jung-gu, Daegu 700-721, Korea

Tel: +82-53-200-5566, Fax: +82-53-426-6722, E-mail: jugkim@knu.ac.kr

**\*Conflicts of Interest:** The authors disclose no potential conflicts of interest.

Copyright © 2015 The Korean Association of Internal Medicine

This is an Open Access article distributed under the terms of the Creative Commons Attribution Non-Commercial License (<http://creativecommons.org/licenses/by-nc/3.0/>) which permits unrestricted noncommercial use, distribution, and reproduction in any medium, provided the original work is properly cited.

generally have remission within a decade after diagnosis, some patients suffer from clinically significant organ damage [1].

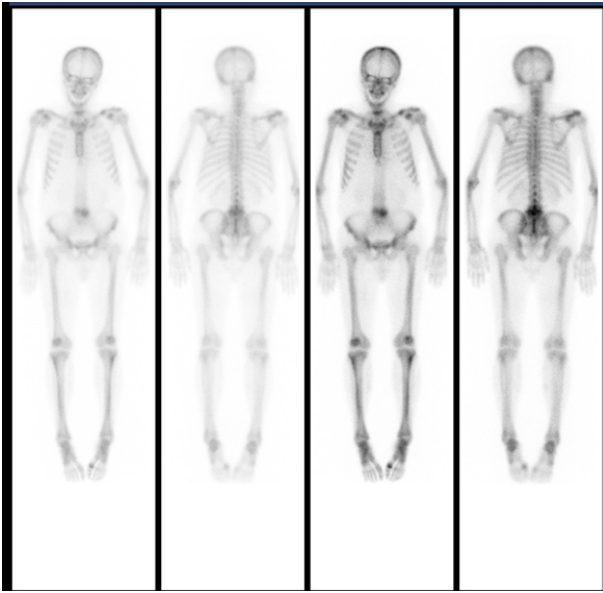
The prevalence of hypercalcemia in sarcoidosis varies from 2% to 63% [2]; however, clinically significant hypercalcemia is infrequent, occurring in approximately 5% of all cases of sarcoidosis with hypercalcemia. Because long-standing hypercalcemia and hypercalciuria is followed by nephrolithiasis and renal insufficiency, adequate management is required. Increased activity of  $1\alpha$ -hydroxylase, which converts  $25(\text{OH})\text{D}$  to  $1,25(\text{OH})_2\text{D}$ , within the granuloma is known to be the main mechanism behind the hypercalcemia in sarcoidosis [1]. Corticosteroid is used to treat sarcoidosis-associated hypercalcemia because it preferentially inhibits  $1\alpha$ -hydroxylase in macrophages without affecting the same enzyme in renal tubular cells [3]. Based on the pathophysiological relationship between serum  $1,25(\text{OH})_2\text{D}$  and calcium level, these two variables are generally correlated strongly and positively. In exceptional cases, however, the serum  $1,25(\text{OH})_2\text{D}$  level is normal despite hypercalcemia. This can hamper diagnosis, as has been reported [4]. Here, we present a case of sarcoidosis-associated hypercalcemia with normal  $1,25(\text{OH})_2\text{D}$  that delayed diagnosis.

## CASE REPORT

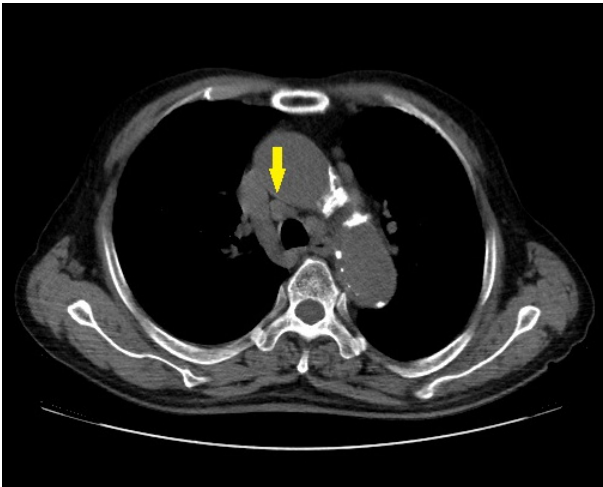
A 77-year-old male visited the outpatient department of Kyungpook National University Hospital (KNUH) for evaluation of his long-standing hypercalcemia. In 2012, he was diagnosed at his local hospital with chronic kidney disease plus hypercalcemia. As his hypercalcemia was not considered to be severe, conservative management such as hydration was performed and he was discharged without any further evaluation. Several months later, 20 days before his admission to KNUH, the patient was admitted to another hospital. Routine chemistry testing revealed hypercalcemia (serum calcium 12.7 mg/dL) that was unresponsive to hydration; indeed, it rose even further to 13.8 mg/dL while the patient was being hydrated. Intriguingly, the patient did not have any other symptoms or signs associated with hypercalcemia. In addition, non-enhanced chest and abdomen computed tomography (CT) did not detect any tumors in the

scanned regions. Therefore, the patient was referred to KNUH for further evaluation of his hypercalcemia. Having previously been diagnosed with essential hypertension, he was taking telmisartan and amlodipine. He had also previously been prescribed with a proton pump inhibitor and theophylline to treat reflux esophagitis and chronic obstructive pulmonary disease, respectively. To our knowledge, he had not been prescribed medications that affect serum calcium levels.

On the day of admission to KNUH, physical examination revealed a blood pressure of 136/83 mmHg and a heart rate of 81/min. The patient's serum calcium and phosphorous levels were 13.9 mg/dL and 4.3 mg/dL, respectively; his 24-h urine calcium level was 963.60 mg/day (normal: 100-300); and his blood nitrogen urea and serum creatinine levels were 25 mg/dL and 3.08 mg/dL, respectively. Ultrasonography of the kidney did not detect nephrolithiasis. A QuantiFERON<sup>®</sup>-TB Gold test showed that the patient was negative for tuberculosis. Since the serum parathyroid hormone (PTH) level (4.42 pg/mL) was low (normal: 8-60 pg/mL), the possibility of primary hyperparathyroidism was ruled out. As tumor metastasis to the bone was the biggest concern, the patient was assessed for the presence of malignancy; however, a  $\text{Tc}^{99\text{m}}$  whole-body bone scan showed no evidence of bone metastasis. Instead, it showed increased linear uptake at lumbar vertebrae 4 and 5, which was suggestive of a compression fracture at this site (Fig. 1). Chest radiography did not detect any nodules or masses, but showed subtle infiltration in both lower lung fields (Fig. 2). Urinary free kappa and lambda chains and M-spikes were negative and the albumin-to-globulin ratio remained normal; thus, multiple myeloma was excluded. Next, a chest CT taken at the previous hospital was carefully reviewed. This revealed the presence of right hilar lymphadenopathy and right lower paratracheal lymphadenopathy, albeit with minimal enlargement (Fig. 3). Importantly, there were subpleural reticular densities in both lower lobes, which were suggestive of usual interstitial pneumonia (UIP) (Fig. 4). It was difficult to interpret the lymphadenopathy because such mild mediastinal lymphadenopathy can be accompanied by not only pulmonary sarcoidosis but also interstitial lung diseases such as UIP. Moreover, the serum  $1,25(\text{OH})_2\text{D}$  level (32.64 pg/mL) was

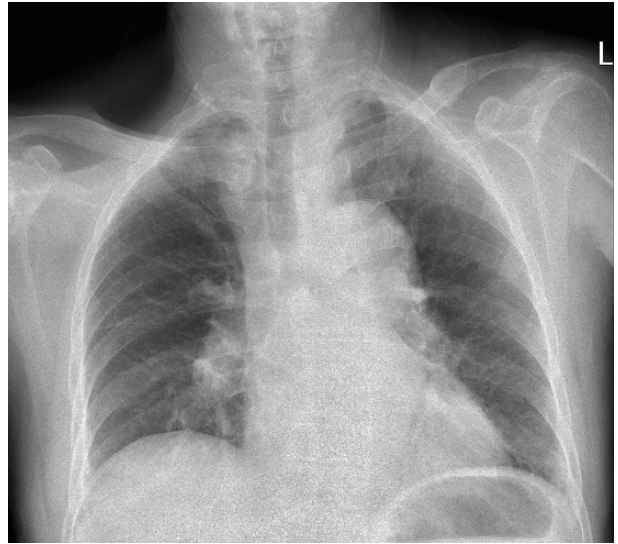


**Figure 1.** Whole-body bone scan showing increased linear uptake at lumbar vertebrae 4 and 5, which is suggestive of a compression fracture. Increased tracer uptake at the left first metatarsophalangeal joint is also present.

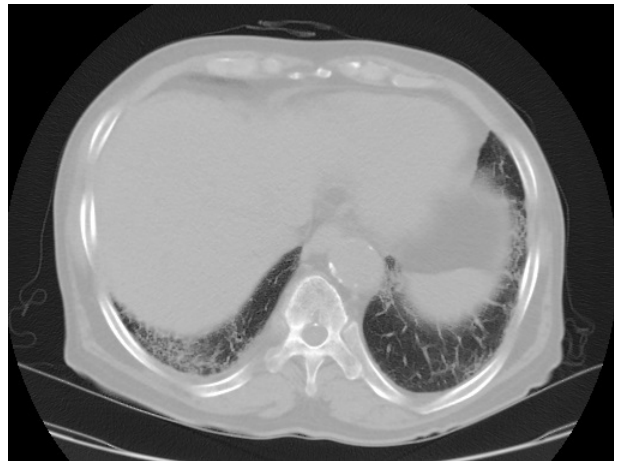

**Figure 3.** Non-enhanced chest computed tomography showing slight enlargement of the right lower paratracheal lymph node (arrow), which is the site from which the biopsy was taken.

within normal limits (normal: 19.60-54.30 pg/mL). However, the serum angiotensin-converting enzyme (ACE) level (245.5 U/L) was markedly increased (normal: 18-55 U/L). Despite the mildness of the hilar lymphadenopathy and the discordance between the serum calcium and 1,25(OH)<sub>2</sub>D levels, the increased serum ACE level was thought to warrant mediastinoscopic biopsy of



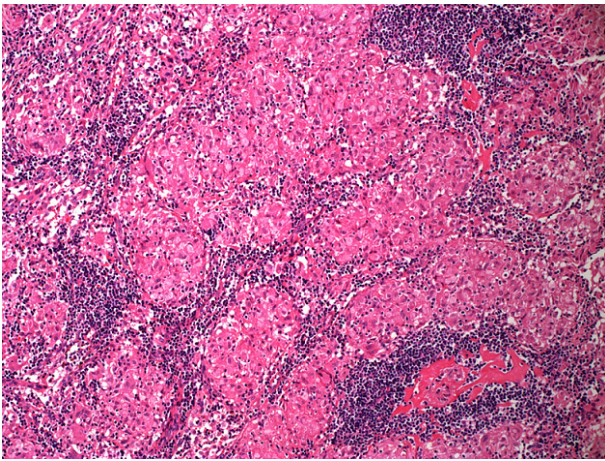
**Figure 2.** Plain chest film showing neither a mass nor remarkable hilar lymphadenopathy. There is increased haziness in both lower lung fields.



**Figure 4.** Non-enhanced chest computed tomography showing increased peripheral reticular densities in both lower lobes.

the right lower paratracheal lymph node. The final pathological diagnosis was non-caseous chronic granulomatous inflammation that was compatible with sarcoidosis (Fig. 5).

Oral prednisone at a dose of 30 mg/day was started, in addition to the well-established treatment options for hypercalcemia such as hydration, furosemide, and pamidronate. At 10 days after oral steroid treatment was initiated, the serum calcium level (8.5 mg/dL) was normalized. The serum creatinine level (2.3 mg/dL) also improved. After 6 weeks of prednisone admin-



**Figure 5.** Hematoxylin and eosin staining of the right lower paratracheal lymph node (original magnification  $\times 100$ ). Non-caseous chronic compact granulomas can be seen.

istration, the serum calcium and serum creatinine levels dropped further to 7.6 mg/dL and 1.81 mg/dL, respectively. The 25(OH)D and 1,25(OH)<sub>2</sub>D levels were 8.58 ng/mL and 27.96 pg/mL, respectively. Currently, the prednisone dose is being tapered to 10 mg/day and the patient is taking calcium and vitamin D supplements to manage his vitamin D deficiency.

## DISCUSSION

This case shows that clinical suspicions are important for the diagnosis of sarcoidosis and that hypercalcemia in granulomatous diseases is not necessarily accompanied by increased serum vitamin D levels. In general, the three most common causes of hypercalcemia are hyperparathyroidism, malignancy, and multiple myeloma. The exclusion of these three diagnoses should prompt physicians to consider other conditions such as granulomatous disease, vitamin D intoxication, and thiazide diuretic use or hyperthyroidism.

The relationship between vitamin D and calcium levels in sarcoidosis was first revealed by a study performed more than 30 years ago, which showed that in sarcoidosis plasma 1,25(OH)<sub>2</sub>D level correlates positively with serum calcium level, regardless of whether it is high or it resolves spontaneously or after treatment with prednisone [5]. The hypercalcemia in sarcoidosis, as well as in other granulomatous diseases such as tuberculosis, is

due to the increased production of 1,25(OH)<sub>2</sub>D by pulmonary alveolar macrophages [6]. This elevation in turn depends on increased 1 $\alpha$ -hydroxylase messenger ribonucleic acids (mRNA) expression in these macrophages [6]. Physiologically, the renal expression of 1 $\alpha$ -hydroxylase is downregulated by 1,25(OH)<sub>2</sub>D but this negative feedback loop does not influence the expression of 1 $\alpha$ -hydroxylase by sarcoid macrophages [7]. This causes the hypercalcemia seen in sarcoidosis.

In terms of the relationship between serum 1,25(OH)<sub>2</sub>D and hypercalcemia in sarcoidosis, a study of 36 Japanese patients with sarcoidosis showed that serum ionized calcium level correlates significantly with serum levels of both 1,25(OH)<sub>2</sub>D level and ACE [8]. In that study, increased serum calcium levels were observed in three patients while increased 1,25(OH)<sub>2</sub>D levels were observed in five patients. Whether all of these individuals with hypercalcemia actually had elevated 1,25(OH)<sub>2</sub>D levels was not reported. Nevertheless, the findings of that study clearly show that extrarenal 1,25(OH)<sub>2</sub>D production is responsible for the hypercalcemia in sarcoidosis. A recent cohort study of 1,606 patients with sarcoidosis conducted by Baughman et al. [9] indicated that 6% of the patients had hypercalcemia and that patients with a history of sarcoidosis-associated hypercalcemia had significantly higher 1,25(OH)<sub>2</sub>D levels than patients with no history of hypercalcemia; however, the two groups did not differ in terms of 25(OH)D levels. Indeed, more than 70% of patients with elevated 1,25(OH)<sub>2</sub>D had low levels of 25(OH)D. These observations support the hypothesis that an increased autonomous 1 $\alpha$ -hydroxylase level is the main cause of the hypercalcemia observed in sarcoidosis. Notably, in the study conducted by Baughman et al. [9] only 4 of the 18 patients with initial hypercalcemia had elevated 1,25(OH)<sub>2</sub>D levels. The discrepancy between serum calcium and 1,25(OH)<sub>2</sub>D levels here is puzzling; however, it is attributed, at least in part, to their expanded definition of hypercalcemia ( $> 10.2$  mg/dL) and widened normal 1,25(OH)<sub>2</sub>D levels (10-75 pg/mL).

Falk et al. [4] reported a case of mediastinal sarcoidosis with hypercalcemia and a normal vitamin D level, similar to our case. A 68-year-old male with a history of mild renal insufficiency presented with hypercalcemia (3.11 mmol/dL) and normal

1,25(OH)<sub>2</sub>D (38 pg/mL) and was finally diagnosed with sarcoidosis [4]. The authors suggested that the hypercalcemia in this patient might have been aggravated by confounding factors (such as coexisting mild renal insufficiency) that promote oral calcium uptake and/or decrease calcium excretion in conjunction with dehydration. Another article reported a case of hypercalcemia due to sarcoidosis with normal vitamin D metabolite levels [10]. Considering the low level of PTH, the authors suggested that “inappropriately normal” vitamin D metabolite level was due to the regulatory feedback mechanisms of vitamin D synthesis. Our patient also presented with a normal serum 1,25(OH)<sub>2</sub>D level despite having hypercalcemia. The reason for these discrepancies is currently unknown and warrants further consideration. One possible explanation is that these patients had an underlying vitamin D deficiency that counterbalanced the activity of the sarcoid macrophages, therefore resulting in normal levels of 1,25(OH)<sub>2</sub>D. Unfortunately, since the serum 25(OH)D level was not measured in our patient before steroid treatment, there is no direct evidence for this notion. Moreover, as suggested by Falk et al. [4], our patient’s volume status and decreased renal function may have exaggerated his hypercalcemia.

In summary, we report here a case of sarcoidosis-induced hypercalcemia with normal serum concentrations of vitamin D, which shows that in certain situations serum 1,25(OH)<sub>2</sub>D levels can be normal in the context of sarcoidosis-induced hypercalcemia. Possible explanations for this are coexisting vitamin D deficiency, dehydration, and renal insufficiency; thus, normal 1,25(OH)<sub>2</sub>D levels alone cannot be used to exclude the possibility of sarcoidosis-related hypercalcemia. Therefore, in such cases, clinical suspicions, measurement of ACE, and radiological examinations are recommended.

**중심 단어:** 고칼슘혈증; 사르코이드증; 비타민 D

## REFERENCES

1. Iannuzzi MC, Rybicki BA, Teirstein AS. Sarcoidosis. *N Engl J Med* 2007;357:2153-2165.
2. Sharma OP. Vitamin D, calcium, and sarcoidosis. *Chest* 1996;109:535-539.
3. Adams JS, Gacad MA. Characterization of 1 alpha-hydroxylation of vitamin D3 sterols by cultured alveolar macrophages from patients with sarcoidosis. *J Exp Med* 1985;161:755-765.
4. Falk S, Kratzsch J, Paschke R, Koch CA. Hypercalcemia as a result of sarcoidosis with normal serum concentrations of vitamin D. *Med Sci Monit* 2007;13:CS133-CS136.
5. Bell NH, Stern PH, Pantzer E, Sinha TK, DeLuca HF. Evidence that increased circulating 1 alpha, 25-dihydroxyvitamin D is the probable cause for abnormal calcium metabolism in sarcoidosis. *J Clin Invest* 1979;64:218-225.
6. Adams JS, Sharma OP, Gacad MA, Singer FR. Metabolism of 25-hydroxyvitamin D3 by cultured pulmonary alveolar macrophages in sarcoidosis. *J Clin Invest* 1983;72:1856-1860.
7. Reichel H, Koeffler HP, Barbers R, Norman AW. Regulation of 1,25-dihydroxyvitamin D3 production by cultured alveolar macrophages from normal human donors and from patients with pulmonary sarcoidosis. *J Clin Endocrinol Metab* 1987;65:1201-1209.
8. Hamada K, Nagai S, Tsutsumi T, Izumi T. Ionized calcium and 1,25-dihydroxyvitamin D concentration in serum of patients with sarcoidosis. *Eur Respir J* 1998;11:1015-1020.
9. Baughman RP, Janovcik J, Ray M, Sweiss N, Lower EE. Calcium and vitamin D metabolism in sarcoidosis. *Sarcoidosis Vasc Diffuse Lung Dis* 2013;30:113-120.
10. Shrayyef MZ, DePapp Z, Cave WT, Wittlin SD. Hypercalcemia in two patients with sarcoidosis and mycobacterium avium intracellulare not mediated by elevated vitamin D metabolites. *Am J Med Sci* 2011;342:336-340.